

Image section: Radiology corner.

Question

A seventy-two year old male presented with 2 hours duration of tearing chest pain radiating to both his arms. ECG revealed elevated ST segments in leads V1-V6. The patient was thrombolysed with streptokinase. Although the patient improved initially, he complained of dizziness around an hour later. His blood pressure was 70/48 and pulse was 126/min. The chest had extensive crepitations bilaterally. A loud holosystolic murmur was heard parasternally in the left fourth intercostal space.

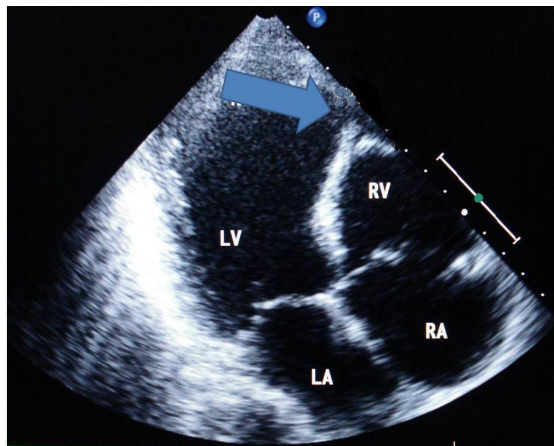


Figure 1

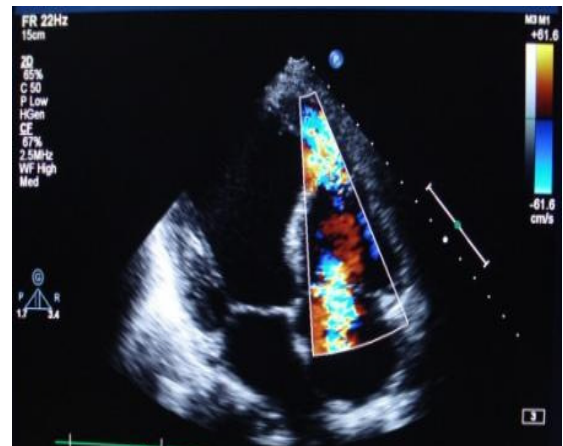


Figure 2

1. What are the possible causes of sudden deterioration?
2. What do the figures reveal?
3. What factors predispose to the occurrence of this catastrophe?