

## Image section – Radiology corner - Questions

50 year old female with acute onset of loss of consciousness.

Fig:1

Plain CT of Head

Fig : 2

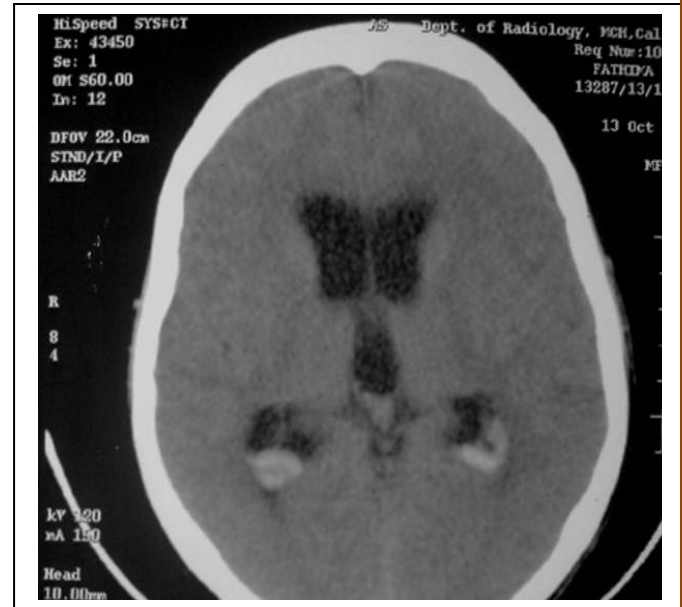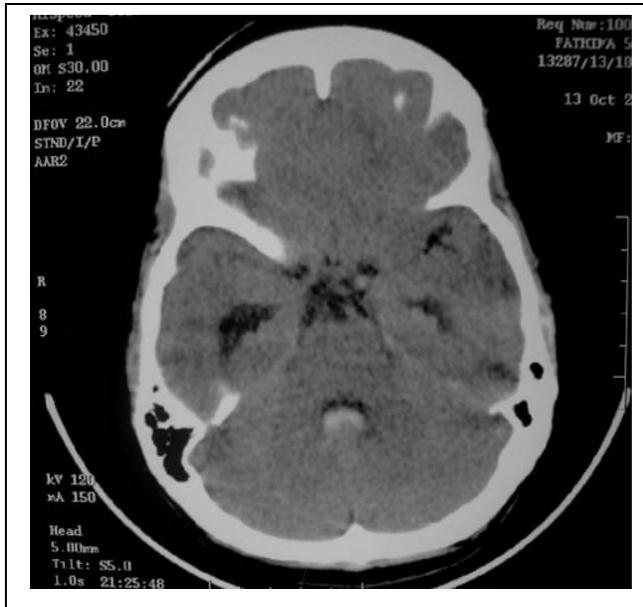

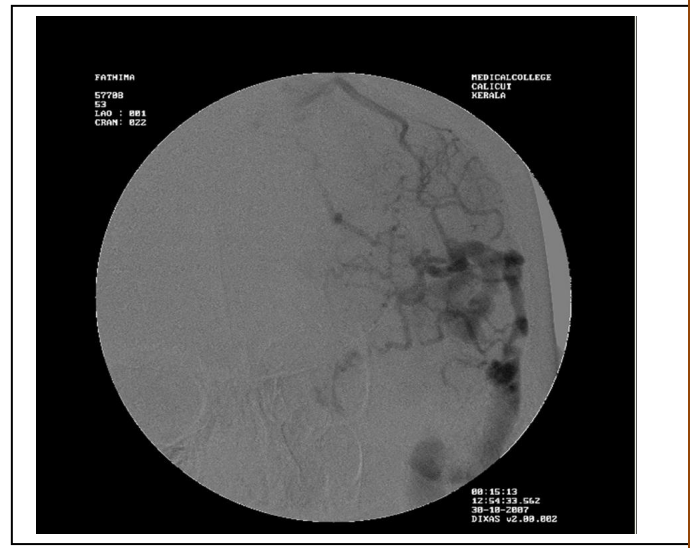
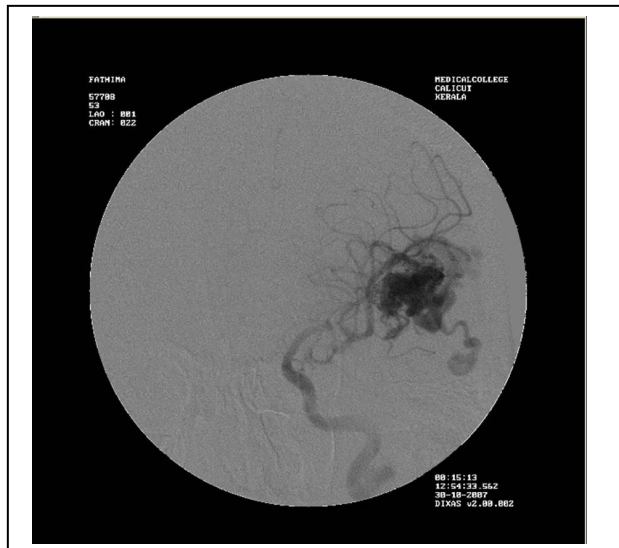Fig: 3

cerebral angiogram

fig :4



1. Identify the radiological abnormalities in these figures?
2. What is the probable diagnosis?

Please check the "Answer" section for the answers