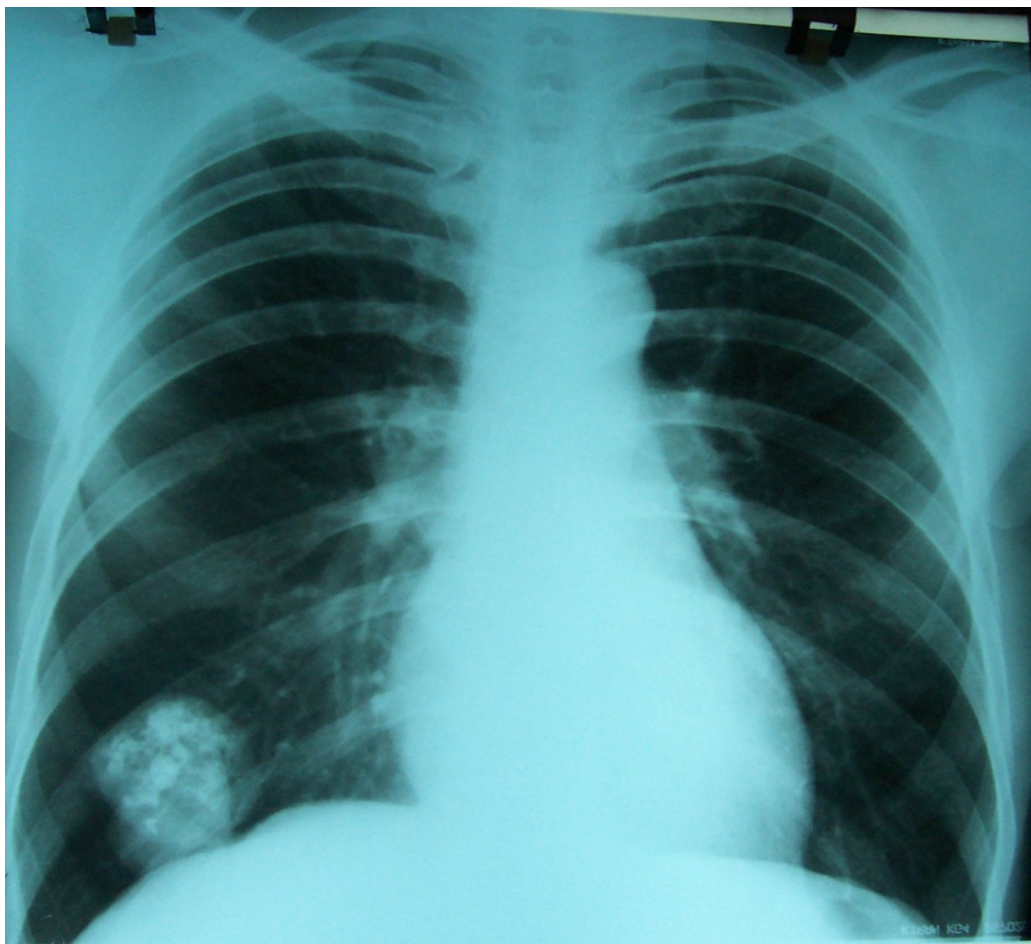


Image section

A 60 year old male patient presented with breathlessness and cough for six months. There was history of streaky haemoptysis for the previous 2 weeks. He was a smoker with no history of tuberculosis in the past. No contributory occupational exposure. The X-ray chest PA view image is shown here.



1) Identify the radiological abnormality in this figure

2) What is the probable diagnosis?

Please check the "Answer" section page for the answers - cmj2008;6(1)e6b.pdf